

CLINICAL IMAGE

MEDICAL QUIZ : IMAGES

Aminur Rahman

Date of submission: 12.04.2025

DOI: <https://doi.org/10.3329/bjm.v36i2.81169>.

Date of acceptance: 19.04.2025

Citation: Rahman A. Clinical Image 1. Bangladesh J Medicine 2025; 36(2): 158

A 60-year-old woman presented with low back pain of 2 months duration, which increased in severity over the last 15 days. The pain was radiating to the left lower limb and was associated with tingling and numbness. The patient had a history of low-grade fever,

weight loss, and malaise over the last 2 months. There was a history of cough with expectoration. On examination, there was mild pallor and no other significant findings. There was localized tenderness over the lumbosacral spine.

An MRI of the lumbosacral spine was done.

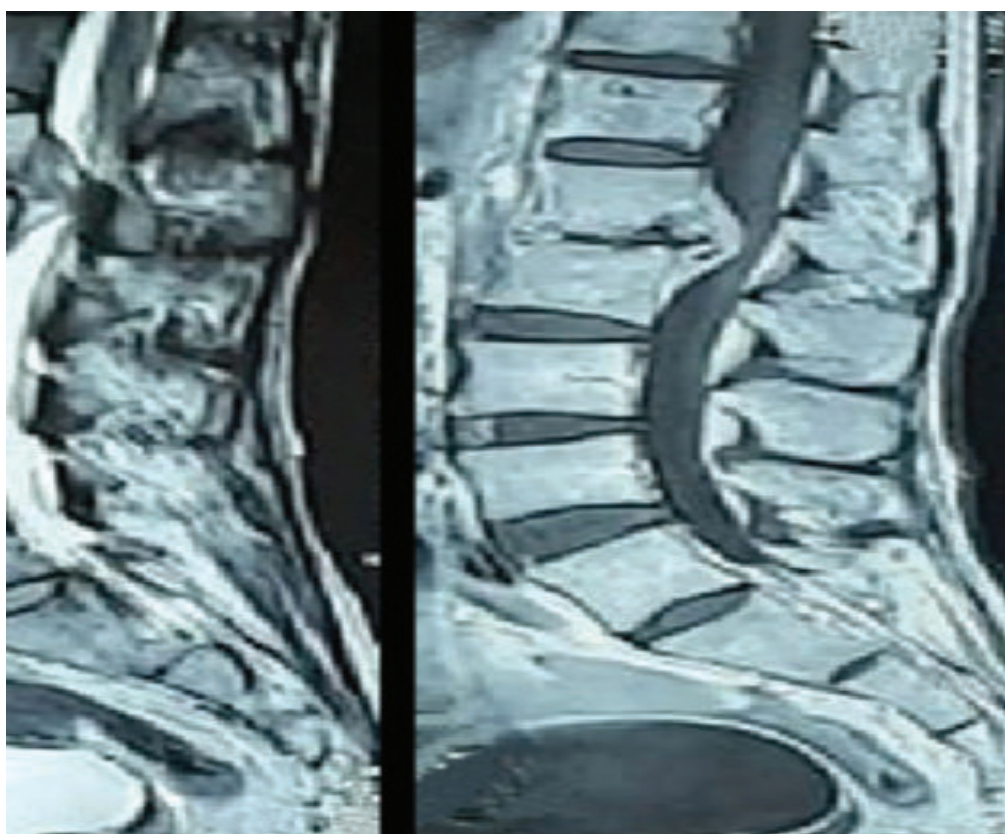


Figure-1: MRI of lumbosacral spine T1-weighted and T2-weighted and T1+C sagittal images of the patient

Please answer the question as above scenarios

- What are the findings of MRI of lumbosacral spine?
- What is the most likely diagnosis?
- How can you confirm the diagnosis?
- What is the gold standard treatment?

Address of Correspondence: Prof. Dr. Aminur Rahman, Professor and Head, Dept. of Neurology, Sir Salimullah Medical College, Dhaka-1100, Bangladesh, E-mail: draminur@yahoo.com, <https://orcid.org/0000-0001-9261-7734>.

Copyright: © 2025 Associations of Physicians of Bangladesh