

CLINICAL IMAGE

MEDICAL QUIZ: IMAGE - 1

MUHAMMAD ABDUR RAHIM

Received: 07.11.2021

DOI: <https://doi.org/10.3329/bjm.v33i1.56803>

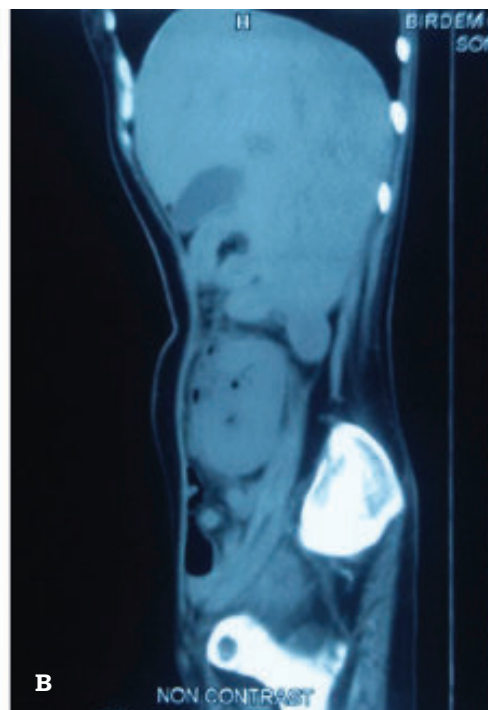
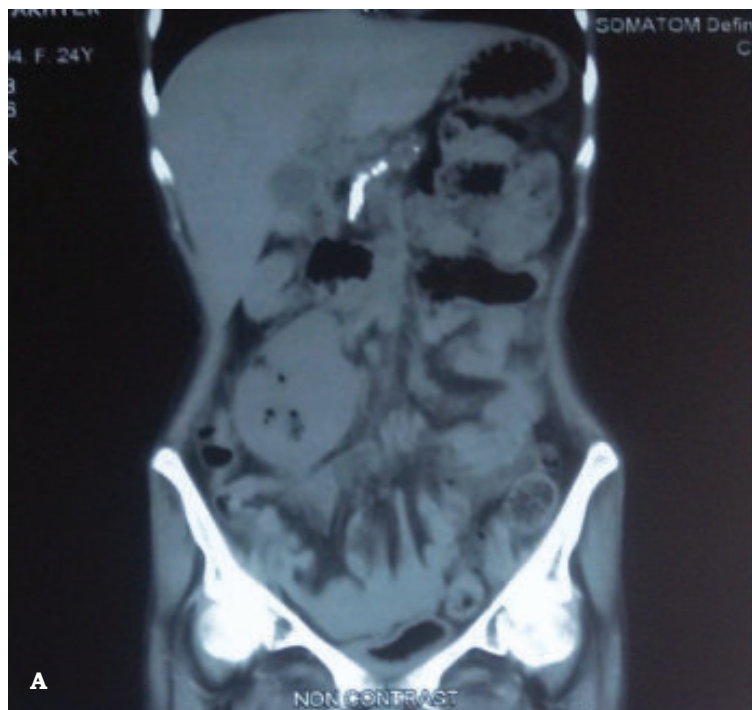Accepted: 09.11.2021

Citation: Rahim MA. Clinical Image. Bangladesh J Medicine 2022; 33: 122

A 24-year-old lady, diagnosed with type 1 diabetes mellitus and stage 5 chronic kidney disease, presented with a 3-day history of fever, dysuria, pain and heaviness in right lower abdomen. Examination revealed a toxic looking lady with fever (102p F), tachycardia and dehydration. There was a tender lump

in right iliac fossa. She was hospitalized under surgery.

She had neutrophilic leukocytosis, plenty of pus cells and red cells on urine routine examination. A non-contrast abdominal computed tomography (CT) scan of abdomen was done and images (A and B) are presented below.



Question 1. Mention abnormal radiological findings.

Question 2. What is the radiological diagnosis?

Question 3. How will you treat such a case?

Address of correspondence: Dr. Muhammad Abdur Rahim, Associate Professor, Department of Nephrology, BIRDEM General Hospital, Dhaka, Bangladesh. E-mail: muradrahim23@yahoo.com

Copyright: ©2021 Associations of Physicians of Bangladesh