

Split Cast Metal Post and Core

S Kunhappan¹, S Patil², P Agarwal³, N Kunhappan⁴

Abstract

This case report presents restoration of an endodontically treated carious broken mandibular first molar with divergent roots, restored with split-cast post and core fabricated by direct technique. Endodontic treatment of a mutilated tooth may prove unfruitful if it is not well restored to bear the forces of occlusion. So the options of prosthetic reconstruction should be well considered before attempting endodontic treatment on badly broken teeth. In such cases post is the choice of restoration as it serves to retain core. Badly broken molar was preserved by using multiple posts in the divergent canals. Non parallel accessory posts was used as it increased the retentive surface area of the cast post and core, minimized the chance of root perforation during tooth preparation and also redistribute the forces of occlusion. An ideal post system should have the ability to distribute the functional stresses evenly along the root surface and produce minimal stress during placement and cementation. The clinician should select the right type of post and core system considering the biological, mechanical and esthetic needs for each individual tooth.

Keywords: Custom made post and core, Direct technique, Non parallel post, Split cast post and core.

Introduction

Posterior teeth lie in the closer proximity of transverse horizontal axis. An endodontically treated posterior tooth should be provided with proper cuspal coverage to prevent its fracture from occlusal forces and at the same time it should be relieved of potentially damaging lateral forces during excursive movements. Posterior teeth often have curved roots and the predominant canal shape is ovoid.

As the commercially available pre-fabricated posts commonly have round cross section and parallel walls, such posts are unlikely to adapt well with the canal walls along their entire interface, with luting cement occupying greater canal space. For these teeth, retention is better achieved by two or more relatively short posts in the divergent canals¹.

Choice between a custom designed post and a prefabricated post should be made by analyzing the canal configuration². Conservative option is to select the post that closely conforms to the canal shape and size because less dentin removal is required and thus enhancing fracture resistance of the tooth as well as retention of the post^{3,4}. It has been suggested that if a canal requires extensive preparation a well adapted cast post and core restoration will be more retentive than a prefabricated post that does not match the canal shape⁵. The cast post and core is custom fitted to the prepared root canal space and designed to resist torsional forces.

Considering the amount of tooth material removal for crown preparation and the amount of dentin removal in access cavity and canal preparation, a passively fitting post- core seems to be the only radiculo-coronal stabilizer for the weakened tooth. In maxillary molars, palatal canal serves as primary site in for hosting post, while mesio-buccal and disto-buccal serve as secondary canals. While in mandibular molar, distal is the primary canal and mesio-buccal and mesio-lingual act as secondary canals.

1. Dr. Sanjeev Kunhappan, MDS , Lecturer, Department of Conservative Dentistry & Endodontics, Government Dental College, Raipur, (Chhattisgarh), India.

2. Dr. Sanjay Patil, MDS, Professor, Department of Conservative Dentistry & Endodontics, Swargiya Dada Saheb Kalmegh Dental College, Nagpur, (Maharashtra), India.

3. Dr Pratibha Agrawal, MDS, Lecturer, Department of Conservative Dentistry & Endodontics, Triveni Institute of Dental Sciences, Hospital & Research Centre, Bilaspur, (Chhattisgarh), India.

4. Dr Neerja Kunhappan, Lecturer, Department of Orthodontics, Government Dental College, Raipur, (Chhattisgarh), India.

Address of Correspondence:

Dr. Sanjeev Kunhappan, MDS, Lecturer, Department of Conservative Dentistry & Endodontics, Government Dental College, Raipur, (Chhattisgarh), India.
E-mail : skunhappan@gmail.com

Case report

A twenty five year old female patient was referred to the Department of Conservative Dentistry and Endodontics with chief complaint of pain in the lower right posterior region since five days. A history of dull pain for last two years was associated with the same tooth. The pain intensified during any thermal stimulus and upon mastication. Patient's medical history was non-contributory. On clinical examination, tooth number 46 was found to have deep carious lesion with undermined lingual wall. The tooth was tender to palpation and percussion. Heat test using gutta percha stick revealed a lingering pain after the removal of stimulus. Radiographic examination revealed occlusal radiolucency involving pulp space and widening of the periodontal ligament space (Fig.1a). The diagnosis of acute irreversible pulpitis with acute apical periodontitis was made. With patient's consent endodontic treatment was started. Working length was established radiographically (Fig.1b) and the canals were obturated with gutta percha (Fig.1c).

After the proper endodontic treatment challenge was to restore the tooth to proper function with a good coronal restoration. As the lingual wall of the crown was grossly undermined treatment option was restoration of the tooth with a custom made cast post and core followed by full crown. As the roots were divergent, a split cast metal post and core (non-parallel) was planned.

Coronal preparation was performed for PFM crown and for fabrication of posts 7 mm of gutta percha was removed from the coronal part of distal canal and 4 mm from the mesio-buccal canal with the help of piezo reamer (Fig.1i). Auto-polymerizing acrylic resin was used to prepare the post pattern for distal canal. Resin was mixed and rolled into thin cylinder. This was then introduced into the pre-lubricated distal canal and pushed to place by dipping in the monomer. Bead brush technique was used to add resin until the post snugly fitted the canal. Resin was not allowed to harden completely within the canal. It was loosened and resealed several times while still in rubbery stage. Once the resin got polymerized, it was removed and the undercuts were identified and trimmed away carefully with the help of scalpel. The post was then trimmed to give it a continuous tapering shape from occlusal to apical direction. Using the same procedure post pattern was also prepared for mesio-buccal canal.

Now the core was prepared attached to post pattern of mesio-buccal canal. Autopolymerizing acrylic resin was mixed and placed in the pulp chamber.

Petroleum jelly was applied over the earlier prepared post pattern of the distal canal and introduced into the distal canal penetrating through the unpolymerized resin of the core material. Petroleum jelly acted as separating media preventing the polymerization of the distal post with the polymerizing core resin. Distal post pattern was repeatedly removed and resealed into the canal to check for its withdrawal from the core material. Once the core material polymerized completely it was removed. Split cast post and core pattern was so prepared, which consisted of a distal post and a mesio-buccal post which had the core attached to it. The core had a pathway in it through which the distal post could be inserted (Fig.1e & f).

The resin patterns for both the canals were separately sprued, invested and casted with Type III cast gold alloy (Fig.1g). After finishing the castings adjustments were first made for the distal post so that it could pass easily through the pathway in the core attached to the mesio-buccal post (Fig.1h). Then both the posts were adjusted to fit properly inside the canals one by one. Final adjustment was done by first placing the mesio-buccal post and core in mesial root and then placing the distal post through it (Fig.1j). Cementation was done using resin cement. The mesio-buccal post and core was luted first followed by distal post (Fig.1d). Final restoration was done with PFM crown (Fig.1k).

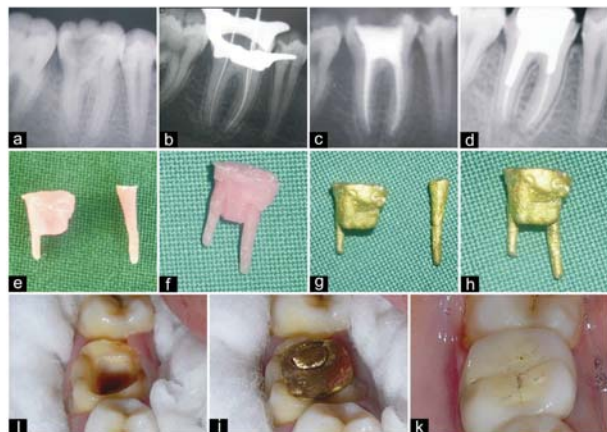


Figure. 1

Discussion

An endodontically treated and restored tooth loses much of its natural tooth structure due to caries decalcification, access cavity preparation and crown preparation. It is this loss of structural integrity rather than the changes in dentin that lead to a higher occurrence of fractures in endodontically treated teeth compared with "vital" teeth⁶.

Access preparations result in increased cuspal deflection during function⁷ and increase the possibility of cuspal fracture and micro leakage at the margins of restorations. Randow and Glantz⁸ reported that teeth have a protective feedback mechanism that is lost when the pulp is removed which may also contribute to tooth fracture.

Consequently such teeth demand a restoration that will not only conserve remaining tooth structure but also provide strength and support to the remaining part. Intra-radicular restorations have been proved to restore such weakened teeth to their natural functions. The choice of these restorations can be made between two systems - conventional custom cast post and core and commercially available prefabricated post systems⁹.

Custom cast posts and cores are generally recommended for posterior as well as anterior teeth with grossly decayed crown structure. The cast post and core is custom fitted to the prepared root canal space and designed to resist torsional forces. According to Morgano¹⁰ and Heydeche¹¹ custom fabricated cast post and cores are still the established technique or gold standard for restoring extensively damaged teeth.

Smith² and Ash¹² stated that canal configuration aids in making a choice between a custom designed post and a prefabricated post. The selected post should closely conform to the canal shape and size to make restoration more conservative as this requires less dentin removal, enhances fracture resistance of the tooth and also enhances retention of the post and core system. The primary reason for using a post is to retain the core that substitutes the missing coronal tooth structure. Therefore the post head design is an important factor. The post head should provide adequate retention and resistance to displacement of the core material. Studies have reported that prefabricated metal posts with direct core made of glass ionomer, composite or amalgam are less reliable than a one piece cast post and core because of the interface between the post and the core.

The recommendations for the split cast metal post and core design discussed here are for the teeth having divergent roots with canals not allowing the same path of insertion for the posts. In this case report there is a different path of insertion for both the posts.

Conclusions

Custom cast post and core are recommended for non circular root canals and when coronal tooth structure loss is moderate to severe. Split cast metal post and core design can be used for additional retention in teeth having divergent roots and in which canals do not allow same path of insertion for the posts.

Simplified design and ease of fabrication are the major advantages of this case report. The technique can be accomplished in any dental clinic without using any complicated equipment.

Clinical Significance

The clinician should select the right type of post and core system considering the biological, mechanical and esthetic needs for each individual tooth. An ideal post system should have the ability to distribute the functional stresses evenly along the root surface, should be esthetically compatible with the definitive restoration and surrounding tissue and produce minimal stress during placement and cementation.

References

1. Rosenstiel, Land, Fujimoto. Contemporary fixed prosthodontics (3rd edition); St Louis: Missouri 2001; 272-312.
2. Smith CT, Schuman N. Restoration of endodontically treated teeth: A guide for the restorative dentistry. Quintessence Int 1994; 28: 457-62.
3. Sorensen JA, Engleman MJ. Effect of post adaptation on fracture resistance of endodontically treated tooth. J Prosthet Dent 1990; 64: 419-24.
4. Craig RG, Farah JW. Stress analysis and design of single restoration and fixed bridges. Oral Sci Rev 1977; 10: 45-74.
5. Cohen BL, Pablillo MK, Condos S, Deutch AS. Four different materials measured for fracture strength in combination with five different design of endodontic posts. J Prosthet Dent 1996; 76: 487-95.
6. Reeh ES. Reduction in tooth stiffness as a result of endodontic restorative procedures. J Endodon 1989; 15: 512-6.
7. Panitvisai P, Messer HH. Cuspal deflection in molars in relation to endodontic and restorative procedures. J Endodon 1995; 21: 57-61.
8. Randow K, Glantz P. On cantilever loading of vital and non-vital teeth. Acta Odontol Scand 1986; 44: 271-7.
9. Barban DJ. The restoration of endodontically treated teeth: An update. J Prosthet Dent 1988; 59: 553-58.
10. Morgano SM, Rodrigues AH, Sabrosa CE. Restoration of endodontically treated teeth. Dental Clinics of North America 2004; 48: 397-416.
11. Heydecke G, Butz F, Strub JR. Fracture strength and survival rate of endodontically treated maxillary incisors with approximal cavities after restoration with different post and core systems: an in vitro study. Journal of Dentistry 2001; 29: 427-33.
12. Ash M Jr. Wheeler's dental anatomy, physiology and occlusion (7th edi), Philadelphia: WB Saunders 1993; 170-217, 274-331.