

# CANDLE Syndrome: Case Report of a Rare Type of Auto-Inflammatory Disease

MD. ASIF ALI<sup>1</sup>, MOHAMMAD IMNUL ISLAM<sup>2</sup>, SHAHANAAKHTAR RAHMAN<sup>2</sup>

## Abstract:

*CANDLE syndrome (chronic atypical neutrophilic dermatosis with lipodystrophy and elevated temperature) is an autoinflammatory disease/syndrome characterized by recurrent fever, skin lesions, and multisystem inflammatory manifestations. Most of the patients have shown mutation in PSMB8 gene. Here, we report a 9-year-old girl with recurrent fever, atypical facies, widespread skin lesions, generalized lymphadenopathy, hepato-splenomegaly, lipodystrophy, and failure to thrive. Considering the clinical features and laboratory investigations including skin biopsy findings, diagnosis was consistent with CANDLE syndrome. Therefore, it is recommended to consider CANDLE syndrome in a young child who presents with recurrent fever, characteristics rashes, organomegaly and failure to thrive.*

**Keywords:** CANDLE syndrome, fever, lipodystrophy

## Introduction:

The hereditary autoinflammatory syndromes/diseases are immune dysregulatory conditions caused by monogenic defects of innate immunity and are classified as primary immunodeficiencies; however, they are not usually associated with increased susceptibility to infections.<sup>1</sup> This syndrome manifest at early childhood with fever and disease-specific patterns of organ inflammation.<sup>2</sup> Proteasome-associated autoinflammatory syndromes (PRAAS) have been described under different terms in the past. This includes four acronyms with similar clinical, laboratory, and genetic features with a spectrum of clinical severity.<sup>3</sup> They are chronic atypical neutrophilic dermatosis with lipodystrophy and elevated temperature (CANDLE syndrome), joint contractures, muscle atrophy, and panniculitis-induced lipodystrophy (JMP syndrome), Nakajo-Nishimura syndrome (NNS), and Japanese autoinflammatory syndrome with lipodystrophy (JASL).<sup>4</sup>

CANDLE syndrome has recently been described as an early-onset autoinflammatory syndrome characterized by early onset of recurrent fever episodes, multiple skin lesions, violaceous periocular edema, arthralgia, specific facial changes, progressive lipodystrophy and hepatosplenomegaly. Lab Investigations showed elevated acute-phase reactants,

altered liver function tests, chronic anemia and central nervous system calcifications.<sup>5</sup> The diagnosis is further confirmed by skin biopsy, which is characterized by atypical, mixed mononuclear and neutrophilic infiltrate.<sup>6</sup> The majority of patients present with homozygous or compound heterozygous mutations in the proteasome subunit  $\beta$  type 8 (PSMB8) gene.<sup>7</sup> A few cases of this rare syndrome are reported till now. We are presenting a case of CANDLE syndrome, which was initially diagnosed as systemic Juvenile Idiopathic Arthritis (JIA) but later on, developed typical clinical features. Laboratory investigations including skin biopsy findings confirmed the diagnosis of CANDLE syndrome.

## Case Report:

A 17-month old baby girl born to a non-consanguineous healthy parent was admitted at Bangabandhu Sheikh Mujib Medical University (BSMMU) with recurrent high-grade fever and erythematous rash since three months of age. After ten months, she developed arthritis of multiple joints. She also had fever, moderate pallor, generalized lymphadenopathy and hepato-splenomegaly. Laboratory findings included microcytic hypochromic anemia with elevated acute phase reactants. The bone marrow study was normal. She was diagnosed as a case of Systemic JIA and was treated with subcutaneous methotrexate (MTX), oral prednisolone and non-steroidal anti-inflammatory drugs (NSAIDs). However, during an attempt to taper the dose of prednisolone, she developed flares; evidenced by fever, rash and arthritis in the multiple joints. She was again treated with Inj. Methylprednisolone

1. Resident, Department of Paediatrics, BSMMU, Dhaka

2. Professor of Paediatrics, Department of Paediatrics, BSMMU.

**Corresponding Author:** Dr. Md. Asif Ali, Resident, Department of Paediatrics, Bangabandhu Sheikh Mujib Medical University (BSMMU), Bangladesh. Cell: 01727211077, E-mail: asifali230789@gmail.com

**Received:** 18/08/2020

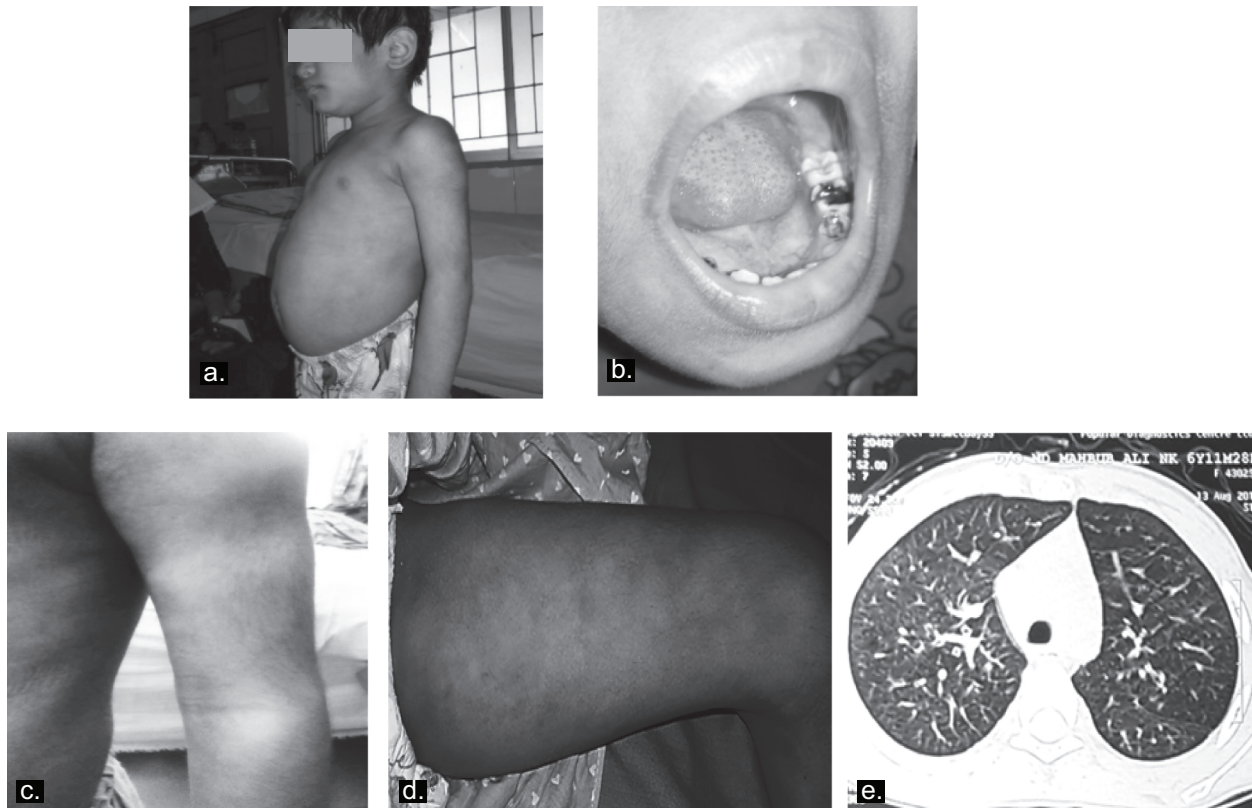
**Accepted:** 7/11/2020

followed by oral prednisolone with symptomatic improvement. Due to repeated flares, after one year Inj. Tocilizumab (12 mg/kg /2 weekly) was added with prednisolone and MTX. Next four years, she was reasonably well and prednisolone was gradually tapered off.

When the girl was eight years old, the disease took a new turn. She again developed recurrent high grade continued fever along with disseminated erythematous nodules and arthralgia. On examination, her skin showed widespread erythematous nodular lesion predominantly on the trunk and extremities, swollen violaceous eyelids, atrophic facial musculature and loss of buccal fat (Fig: A, B) She also had livedoreticularis, lipodystrophy affecting cheeks and extremities, dental caries and muscle atrophy in the limbs.(Fig:A,B,C) Her abdomen was protruded and had hepatosplenomegaly. (Fig: D) She was moderately underweight (WAZ: -2.9 SD) and severely stunted (HAZ: -5.1 SD).Eye examination and hearing screening were normal.

Laboratory workup showed microcytic hypochromic anemia with neutrophilic leukocytosis,

thrombocytosis, high ESR and CRP levels. Her fasting blood sugar was high, and the HOMA-IR index indicated insulin resistance. Other investigations showed highly elevated serum ALT and triglycerides. Quantitative immunoglobulin and lymphocyte subset (CD19, CD3, CD4, CD8, CD56) analyses were normal. Her HRCT showed bronchiectatic changes, which was suggestive for interstitial lung disease (ILD). (Fig:E) Skin biopsy revealed predominantly neutrophilic lobular panniculitis with histiocytic aggregates. Genetic analysis did not detect PSMB8 mutation but it couldn't completely rule out its possibility. Heterogeneity or other causes of CANDLE syndrome might be responsible for this.<sup>8</sup> From history, clinical features and investigations, we diagnosed the girl as Candle Syndrome. Now this girl is on our regular follow-up and receiving oral Baricitinib (JAK-1 and 2 inhibitor) with symptomatic improvement. Evidences of systemic inflammation like fever and rash have disappeared after initiation of treatment. Now she can perform her physical activities normally.



**Fig:** Different morphological features characteristics of CANDLE syndrome in our patient. *a* :Lipodystrophy affecting face ,cheeks with protruded abdomen. *b* : Dental caries. *c,d* : erythematous rash and nodules on extremities. *e* : Features of ILD in the HRCT .

**Discussion:**

Autoinflammatory syndromes/diseases are a group of illnesses characterized by attacks of unprovoked inflammation without significant levels of either autoantibodies or antigen-specific T cells. CANDLE is an autosomal recessive disease, and gene expression profile has shown a robust interferon signature.<sup>9</sup> Most patients present with homozygous or compound heterozygous mutations in the proteasome subunit  $\beta$  type 8 (PSMB8) gene.<sup>7</sup> This gene degrades proteins in immune cells for presentation on major histocompatibility complex class I molecules. Recently, it has been shown that CANDLE syndrome can also be caused by mutations in genes that encode other proteasome subunits, such as PSMB4, PSMB9, and PSMA3.<sup>10</sup>

Gonul M et al. in their study, observed that CANDLE syndrome occurs at early infancy with recurrent fever, skin manifestations, facial lipodystrophy, low weight and height, and protuberant abdomen due to increased intra-abdominal fat and hepatosplenomegaly.<sup>11</sup> Our patient initially did not have typical features, but she later on developed similar findings. Torrelo et al. in their case series have shown four cases of CANDLE syndrome with consistent clinical findings. Among them, one patient showed features of aseptic meningitis, nephritis, interstitial lung disease (ILD) and basal ganglia calcifications.<sup>6</sup> We found features of ILD in the HRCT in our case.

Laboratory abnormalities in CANDLE syndrome include non-specific chronic inflammatory alterations, such as chronic anemia, leukocytosis, thrombocytosis, and increased acute phase reactants. Elevated transaminases and triglycerides may also present.<sup>6,11,12</sup> Our patient also had similar laboratory findings. High fasting blood sugar and HOMA IR index indicating insulin resistance was the other characteristic finding of our case, which was similar in a case report described by Wang et al.<sup>13</sup>

Besides these characteristics, skin biopsy showing mononuclear interstitial infiltrate, including immature neutrophils in the dermis was reported as pathognomonic for CANDLE syndrome.<sup>6</sup> Predominantly neutrophilic lobular panniculitis with histiocytic aggregates was the skin biopsy result of our patient, which was related to a previous case study.<sup>5</sup>

As this reported case had fever, anemia and hepatosplenomegaly as presenting features, it also should

be considered in the differential diagnoses of hematological malignant or nonmalignant disorders. Normal bone marrow examination excluded these conditions in this girl. Normal results of Immunoglobulins and lymphocyte subset analysis excluded Primary immune deficiency disorders (PIDs) also. Sweet syndrome is another important differential diagnosis according to the skin biopsy findings. It is a rare skin illness characterized by fever, leukocytosis and tender, erythematous, well-demarcated papules and plaques on the trunk and extremities.<sup>13</sup> But in our patient, skin lesions were non-tender. Other clinical and laboratory features of our case also excluded sweet syndrome.

Although her disease course and clinical presentations were typical of CANDLE syndrome, genetic analysis for the PSMB8 gene revealed absent mutation suggesting another possible genetic cause for this syndrome. Liu et al. in their study showed similar observations.<sup>8</sup> They did not identify PSMB8 mutation in their patients and suggested there may be heterogeneity and other genetic causes underlying CANDLE syndrome.

CANDLE syndrome responds partially to high doses of oral glucocorticoid and intravenous methylprednisolone.<sup>14</sup> Immunosuppressive agents including azathioprine, methotrexate, and cyclosporine were not proven useful in most of the series.<sup>3,10,14</sup> TNF- $\alpha$  inhibitors, IL-1 receptor antagonist, and anti-IL-6 therapy have been reported with variable response.<sup>3</sup> We treated the girl initially with NSAIDs, MTX and inj. Methylprednisolone followed by oral prednisolone in an attempt to taper the dose with time. She was stable after adding IL-6 blocker (Inj. Tocilizumab) for four years with symptomatic improvement. However, at the age of eight years, she developed typical features of CANDLE syndrome.

CANDLE syndrome presents with a type I interferon signature. It has been suggested that JAK inhibitors may ameliorate the clinical manifestations in these patients.<sup>8,15</sup> An ongoing study using JAK inhibitor seems to improve the clinical manifestations of CANDLE syndrome.<sup>4</sup> We also observed some improvement with JAK inhibitor treatment in our patient.

In conclusion, this girl with CANDLE syndrome was initially treated as a case of systemic JIA. This may signify that a higher degree of suspicion and close monitoring of disease progression is required to

distinguish this newly diagnosed entity of disease from other clinically overlapping disorders.

### References:

1. Al-Herz W, Bousfiha A, Casanova JL, Chatila T, Conley ME, Cunningham-Rundles C et al. Primary Immunodeficiency Diseases: an Update on the Classification from the International Union of Immunological Societies Expert Committee for Primary Immunodeficiency. *Front Immunol* 2014; 5: 162.
2. Jesus AA, Fujihira E, Watase M, Terreri MT, Hilario MO, CarneiroSampaio M et al. Hereditary Autoinflammatory Syndromes: a Brazilian Multicenter Study. *J Clin Immunol* 2012; 32: 922-32.
3. Sanchez GA, DeJesus AA, Goldbach-Mansky R. Monogenic Autoinflammatory Diseases: Disorders of Amplified Danger Sensing and Cytokine Dysregulation. *Rheum Dis Clin N Am* 2013; 39: 701-34.
4. McDermott A, Jacks J, Kessler M, Emanuel PD, Gao L. Proteasome-Associated Autoinflammatory Syndromes: Advances in Pathogenesis, Clinical Presentations, Diagnosis, and Management. *Int J Dermatol* 2015; 54: 121-29.
5. Torrelo A. CANDLE Syndrome as a Paradigm of Proteasome Related Autoinflammation. *Front Immunol* 2017; 8:doi: 10.3389/fimmu.2017.00927
6. Torrelo A, Patel S, Colmenero I, Gurbindo D, Lendinez F, Hernandez A et al. Chronic Atypical Neutrophilic Dermatitis with Lipodystrophy and Elevated Temperature (CANDLE Syndrome). *J Am Acad Dermatol* 2010; 62: 489-95.
7. Gomes AV. Genetics of Proteasome Diseases. *Scientifica* 2013;2013:1-30.doi.org/10.1155/2013/637629
8. Liu Y, Ramot Y, Torrelo A, Paller AS, Si N, Babay S, et al. Mutations in Proteasome Subunit beta type 8 cause Chronic Atypical Neutrophilic Dermatitis with Lipodystrophy and Elevated Temperature with Evidence of Genetic and Phenotypic Heterogeneity. *Arthritis Rheum* 2012; 64: 895-907.
9. Barron SK, Kaster DL. Periodic Fever Syndromes and Other Inherited Autoinflammatory Diseases. In: Petty R, Laxer R, Lindsley C, Wedderburn L. *Textbook of Pediatric Rheumatology*. 7<sup>th</sup> Ed. USA: Saunders; 2016. p. 609-26
10. Verbsky JW. Hereditary Periodic Fever Syndromes and Other Systemic Autoinflammatory Diseases. In: Kliegman RM, Geme JS. Editors. *Nelson Textbook of Pediatrics*. 21<sup>st</sup> Edition. Elsevier; Netherlands. 2020. p. 1303-04
11. Gonul M, Cevirgen Cemil B, Keseroglu HO, Kaya Akis H. New Described Dermatological Disorders. *Biomed Res Int* 2014: 616973.
12. Tripathi SV, Leslie KS. Autoinflammatory Diseases in Dermatology: CAPS, TRAPS, HIDS, FMF, Blau, CANDLE. *Dermatol Clin* 2013; 31: 387-404.
13. Wang H, Das L, Tiong JT, Vasawala RF, Arkachaisri T. CANDLE syndrome: an Extended Clinical Spectrum. *Rheumatology* 2014; 53: 2119-20.
14. Tufekci O, Bengoa SY, Karapınar TH, Ataseven EB, Irken G, Oren H. CANDLE Syndrome: A Recently Described Autoinflammatory Syndrome. *JPediatr Hematol Oncol* 2015; 37:296–99.
15. Boyadzhiev M, Marinov L, Boyadzhiev V, Iotova I, Aksentjevich I, Hambleton S. Disease Course and Treatment Effects of a JAK Inhibitor in a Patient with CANDLE Syndrome. *Pediatric Rheumatology* 2019; 17: 19.