

Case Reports

Ellis-van Creveld Syndrome: A Case Report

ASHITH CHANDRA DAS¹, MD TAREK AZAD², JANNATUL FERDUSH CHOWDHURY³

Introduction

Ellis-van Creveld (EVC) syndrome is a complex genetic disorder having autosomal recessive inheritance which is also called chondroectodermal dysplasia, mesoectodermal dysplasia or chondrodystrophy syndrome.¹ It is a syndrome affecting the Amish population of Pennsylvania in USA with the prevalence rate of 1/5,000 live birth. In non-Amish population, the birth prevalence is 7/1,000,000.² It was first described in 1940 by Richard W. B. Ellis and Simon van Creveld and they termed it chondroectodermal dysplasia.³ Etiology of this syndrome is still speculative. However recent identification of EVC gene has led to a better understanding of this syndrome. The EVC gene has been mapped to chromosome band 4p16 using linkage analysis. Mutations in a second gene, called EVC2 also give rise to the same phenotype of the syndrome.⁴ The tetrad of chondrodystrophy, post axial polydactyly, ectodermal dysplasia and congenital heart disease characterize this syndrome and affects both males and females equally.^{5,6}

Case Report

An eight month old male child admitted in paediatric department of Jalalabad Ragib Rabeya Medical College Hospital, Sylhet with the complaints of fever, cough and respiratory distress for 10 days. There was history of gross motor delay (no neck control at 8 months of age). He was the third issue of his consanguineous parents. His first sibling was still born & second sibling died during perinatal period who had history of skeletal deformity. On examination, the baby was febrile with a respiratory rate of 64/min with chest indrawing and a heart rate of 160/min. There was no cyanosis. On auscultation, crackles was present over both lung fields with a pansystolic murmur grade 4/6, best heard on lower left sternal border without any radiation. His weight was 4.5 kg, height was 54 cm, upper segment was 35 cm and lower segment was 19 cm. upper

segment lower segment ratio was 1.8:1. His OFC was 38.5 cm (-3 SD), WHZ -1 SD, WAZ -4. LAZ -2.4.

The patient had multiple skeletal anomalies including short broad hands and feet with distal shortening of both upper and lower limbs, post axial polydactyly in both hands (with 6 digit each), dystrophic nails in both hands and feet (Fig.-1,2). The patient also had narrow thorax (Fig.-1), high arched palate and the sulcus between upper lip and gum was obliterated.

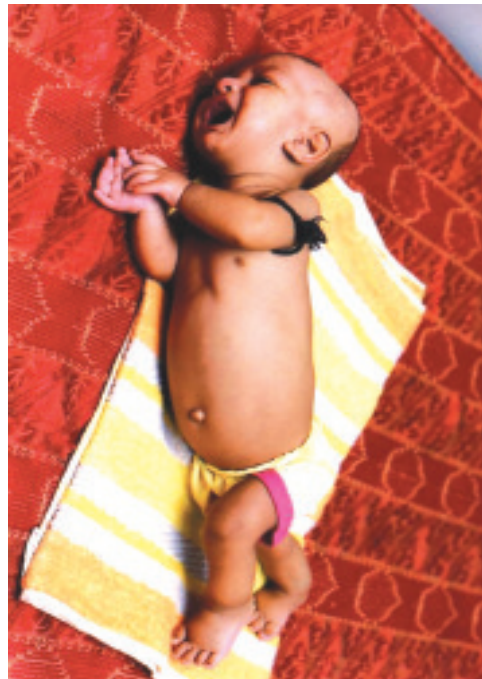

Fig.-1: Short, broad hands and feet, narrow thorax.

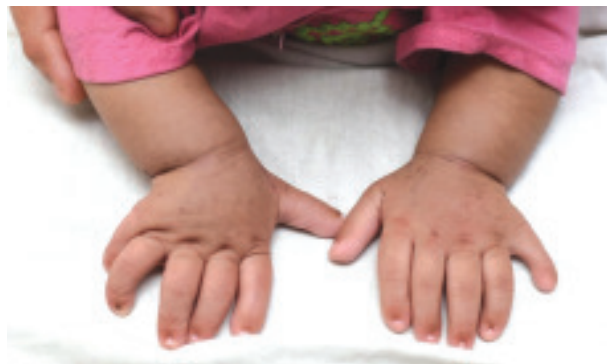

Fig.-2: Bilateral post axial polydactyly with dystrophic nails.

1. Assistant Professor, Department of Paediatrics, Jalalabad Ragib Rabeya Medical College, Sylhet.

2. Professor and Head, Department of Paediatrics, Jalalabad Ragib Rabeya Medical College, Sylhet.

3. Indoor Medical Officer, Department of Paediatrics, Jalalabad Ragib Rabeya Medical College Hospital, Sylhet.

Correspondence: Assistant Professor, Department of Paediatrics, Jalalabad Ragib Rabeya Medical College, Sylhet. E-mail: ashith_das@yahoo.com

Laboratory investigations revealed neutrophilic leukocytosis with microcytic hypochromic anemia. On chest X ray there was patchy opacities over both lung field and cardiomegaly with narrow chest and short ribs (Fig.-3). X-ray pelvis showed small, square iliac crest, spikes of bone at the triradiate cartilage (Fig.-4).

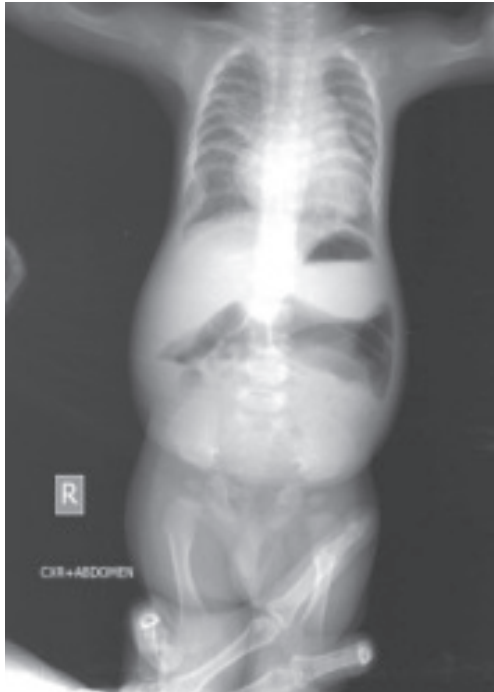

Fig.-3: X-ray chest including abdomen showing narrow thorax, patchy opacities in both lung fields with mild cardiomegaly.

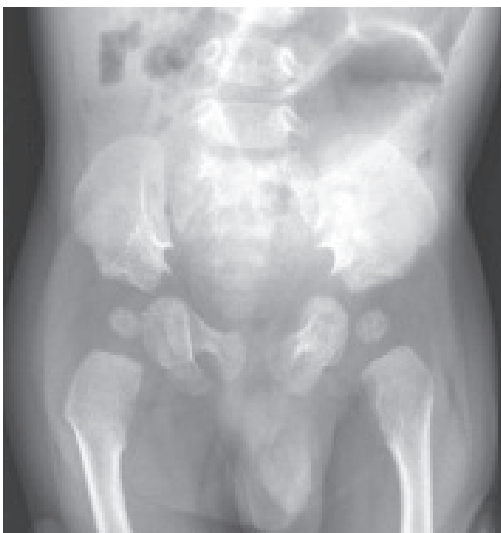

Fig.-4: X-ray pelvis showing small, square iliac crest with spikes of bone at the triradiate cartilage.

X-ray hand showed 6th metacarpal and phalanx on the ulnar border of the both hands (Fig.-5). X-ray lower limbs showed tibial segments were disproportionately shorter than the femoral segments with expanded and abnormally shaped metaphysis of long bones (Fig.-6). Perimembranous VSD with single atrium was found on color Doppler echocardiography.

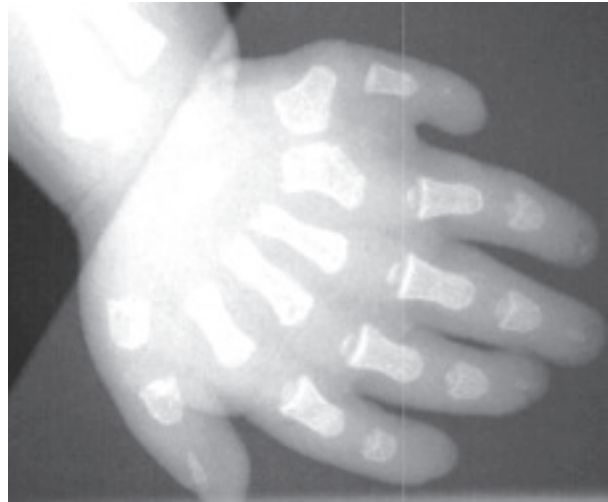


Fig.-5: X-ray hand showing 6th metacarpal and phalanx on the ulnar border of the hand.

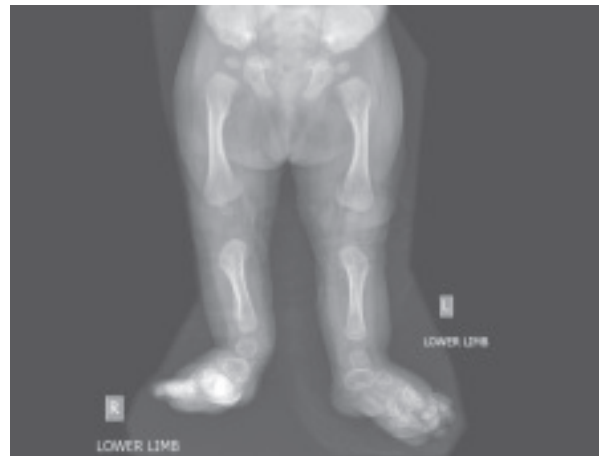

Fig.-6: X-ray lower limbs showing tibial segments are disproportionately shorter than the femoral segments with expanded and abnormally shaped metaphysis of long bones.

Based on clinical features, skeletal survey and echocardiography reports we came to a diagnosis of Ellis-van Creveld Syndrome with bronchopneumonia. Child was treated for pneumonia. After improvement the baby was referred to paediatric cardiologist for management of congenital heart disease.

Discussion

Clinical presentation of EVC syndrome is variable and affects multiple organs. Very rarely these children can present in the neonatal period with skeletal anomalies, natal teeth, respiratory distress and congestive cardiac failure. However most of them present late and may be due to symptoms associated with chondrodystrophy like disproportionate dwarfism with progressive distal limb shortening, symmetrically affecting the forearms and legs.⁶

This syndrome is a tetrad of chondrodystrophy, polydactyly, ectodermal dysplasia and congenital heart defects.^{5,6} Chondrodystrophy means disproportionate dwarfism i.e. normal trunk with symmetrical shortening of middle and distal extremities.³ All four classical signs were present in our patient.

Polydactyly which is usually bilateral and post axial, most often found in the upper limbs and involves the lower limbs in about 10% of the cases.^{7,8} Polydactyly was present only in both upper limbs in our case.

Dystrophic nail which is a feature of ectodermal dysplasia was present in both hands and feet in the present case. Ectodermal dysplasia is present in almost 93% of cases of EVC syndrome and includes hypoplastic, dystrophic nails which may sometimes totally absent. Hair and eyebrows may be sparse.⁷

Congenital heart anomalies are known to occur in 50-60% of cases, most common of them being a common atrium (40%). Other cardiac anomalies include defects in mitral and tricuspid valves, patent ductus arteriosus, ventricular septal defect, atrial septal defect and hypoplastic left heart syndrome.⁹ Common atrium with perimembranous ventricular septal defect was present in this patient.

Multiple orodental abnormalities may be found in this syndrome. Among them fusion of the anterior portion of the upper lip to the maxillary gingival margin, resulting in absence of the mucobuccal fold is characteristics of this syndrome. The other oral manifestations include lip tie, malocclusion, labiogingival adherences, gingival hypertrophy, labiogingival frenulum hypertrophy, accessory labiogingival frenula, dental transposition, conical teeth, enamel hypoplasia, hypodontia and anodontia.¹⁰ Oral abnormalities found in this patient were absence of mucobuccal fold and high arched palate.

Genitourinary abnormalities are seen in about 22% of the cases and include hypospadias, epispadias, hypoplastic penis, vulvar atresia, megaureters and renal agenesis.⁷ Other features include low set shoulders, narrow thorax and knock knees. Although most patients have normal intelligence, occasional CNS anomalies and hydrocephaly have been noted with the association of Dandy-Walker malformation in some rare cases.^{7,11} Narrow thorax was also present in our patient.

EVC syndrome should be differentially diagnosed from two conditions with overlapping features like asphyxiating thoracic dystrophy and short rib polydactyly syndrome. The central feature of asphyxiating thoracic dystrophy is small chest that appears long and narrow. The main distinguishing feature is the absence of hypoplastic nails of hands and feet and asymmetrical presence of polydactyly, but in EVC syndrome symmetrical presence of polydactyly and hypoplastic nails are noted. The other condition, which should be considered due to common features, is short rib polydactyly syndrome. It is characterized by underdeveloped lungs, polydactyly, cleft lip and palate, kidney and intestinal malformations. But in the present case the lungs, kidney and intestine were normal.²

Ellis-van Creveld syndrome involves all embryonic tissue layers and is polysymptomatic. On the basis of bilateral postaxial polydactyly, short middle and distal extremities, dysplastic nails and teeth one can suspect the diagnosis of this syndrome and further skiagram and echocardiography will support the diagnosis of this syndrome. The definitive diagnosis is molecular based on the homozygosity for a mutation in the EVC1 and/or EVC2 genes by direct sequencing. However the genetic mutations are seldom required for the clinical diagnosis. Perinatal diagnosis can be made with intrauterine growth retardation, skeletal malformations and cardiac defects on ultrasound images.

The management of EVC syndrome is multidisciplinary. Pediatric, cardiac, genetic, pulmonologic, urologic, physical and occupational therapeutics as well as psychological and rehabilitative management is needed. Orthopedic care should be sought in combination with surgical, orthodontic prosthodontic regimen to correct craniofacial morphology and teeth defects.

The prognosis of this syndrome is linked to the respiratory difficulties in the initial months of life and these difficulties are related to thoracic narrowness and underlying heart disease. The longevity of survival in children with EVC syndrome depends on the severity of underlying heart disease.¹²

Conclusion

Ellis-van Creveld syndrome is a rare disease of autosomal recessive inheritance. This syndrome is diagnosed mainly by its clinical features and supported by X-ray and echocardiographic findings. Multidisciplinary approach is needed to manage these patients.

References:

1. Varela M, Ramos C. Chondroectodermal dysplasia (Ellis-van Creveld syndrome): a case report. *Europ J of Orthodon.* 1996; 18: 313-18.
2. Kurian K, Shanmugam S, Harsh Vardah T, Gupta S. Chondroectodermal dysplasia (Ellis van Creveld syndrome): a report of three cases with review of literature. *Indian J Dent Res.* 2007; 18: 31-34.
3. Horton WA, Hecht JT. Disorders for which defects are poorly understood or unknown. In: Behrman RE, Kliegman RM, Jenson HB, editors. *Nelson's Textbook of Paediatrics.* 19th ed. Philadelphia: WB Saunders; 2433-34.
4. Galdzicka M, Patnala S, Hirshman MG, Cai JF, Nitowsky H, Egeland JA et al. A new gene, EVC2, is mutated in Ellis-van Creveld syndrome. *Mol Genet Metab.* 2002; 77: 291-95.
5. Shah B, Ashok L, Sujatha GP. Ellis-van Creveld syndrome: a case report. *J of Indi Socie of Pedodon and Preve Dentis.* 2008; 26:19-22.
6. Jenkins S, Morrell DS. Ellis-van Creveld syndrome: case report and review of the literature. *Pediatr Dermatol.* 2009; 83: 303-05.
7. Amin A, Ahmed T, Ashraf M, Lone Z, Wani I. Chondroectodermal dysplasia (Ellis-van Creveld syndrome): a case report. *The Internet Journal of Pediatrics and Neonatology.* 2008; 10: 1.
8. DaSilva EO, Janovitz D, de Albuquerque SC. Ellis-van Creveld syndrome: report of 15 cases in an inbred kindred. *J Med Genet.* 1980; 17: 349-56.
9. Baujat G., Le Merrer M. Ellis-van Creveld syndrome. *Orphanet Journal of Rare Diseases.* 2007; 2: 27.
10. Winter G, Geddes M. Oral manifestations of chondroectodermal dysplasia (Ellis-van Creveld syndrome): report of a case. *Br Dent J.* 1967; 122: 103-07.
11. Zanzwill KM, Boal DK, Ladda RL. Dandy Walker malformation in Ellis-van Creveld syndrome. *Am J Med Genet.* 1988; 31: 123-29.
12. Digilio M, Marino B, Ammirati A, Borgaza U, Gianotti A, Dallapiccola B. Cardiac malformations in patients with oral-facial skeletal syndromes: clinical similarities with heterotaxia. *Am J Med Genet.* 1999; 84: 350-56.