

MEDICAL QUIZ

(Birdem Med J 2012; 2(2): 129-130)

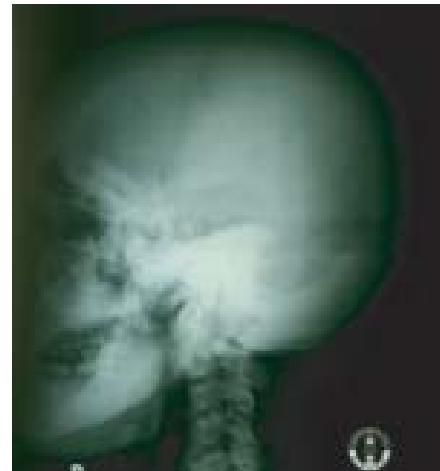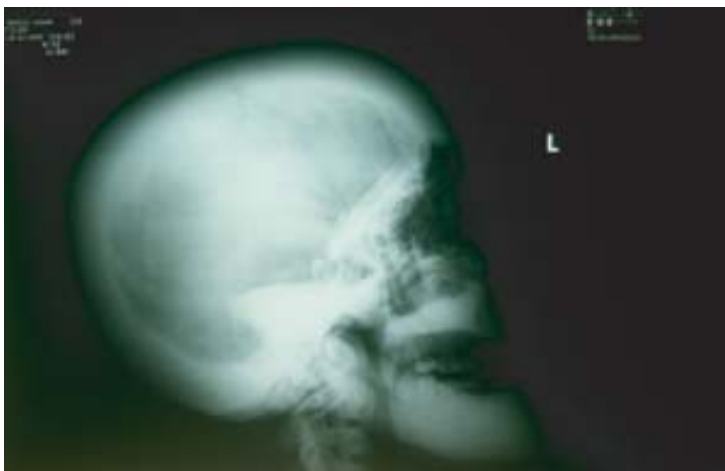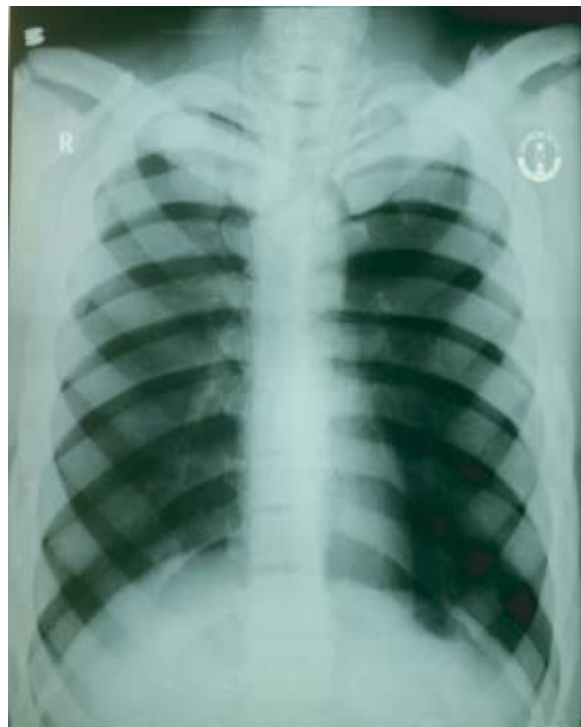Medical Quiz : Images

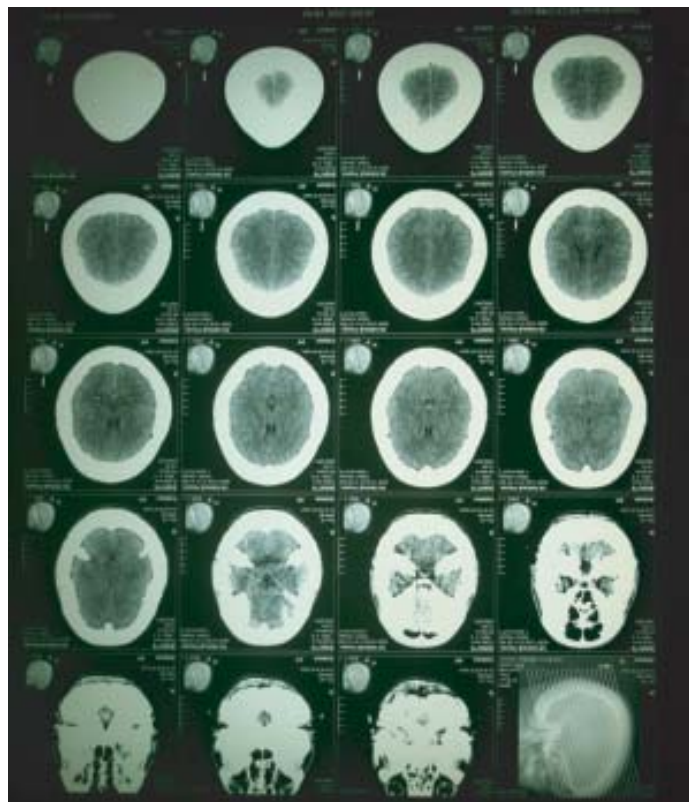
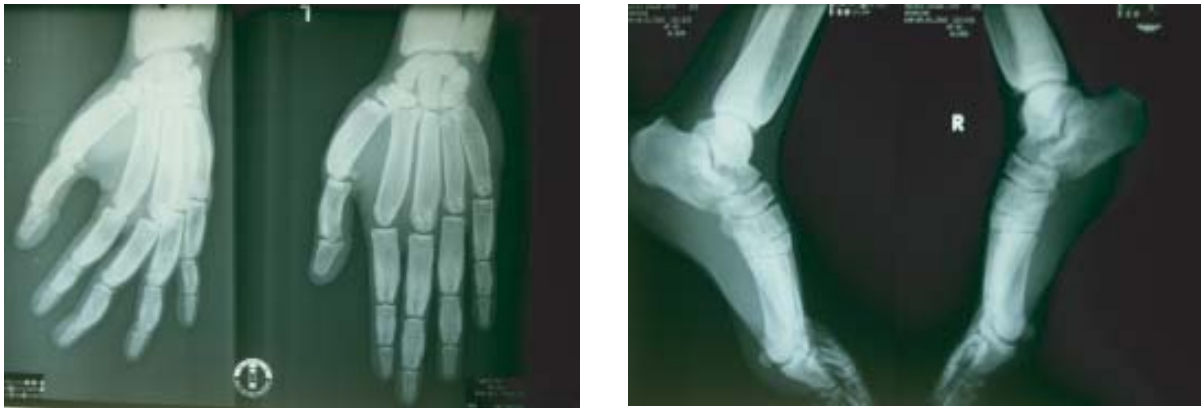A.M.B. SAFDAR

Assistant Professor; Cardiology, BIRDEM General Hospital

A 28 year-old young man got admitted under endocrinology department of BIRDEM General Hospital with the complaints of headache along with dizziness for

one month, two episodes of convulsion over two months & gradual enlargement of facial bone for three years .The images are given below. What is the diagnosis?





See Answer Page No. 139