

The relationship between duration of diabetes mellitus and bone mineral density in post-menopausal female diabetic patient with diabetic retinopathy

Mira MS^a, Ruma ZJ^b, Debnath PR^c

ABSTRACT

Background: Diabetic retinopathy is a complication of diabetes caused by high blood sugar level affecting the eyes. The duration of diabetes appears to be an important risk factor for fractures. Chronic hyperglycemia is widely documented to have an effect on bone health, causing fragility, mechanical strength decrease and an increased susceptibility to fracture due to altered bone matrix microstructure and aberrant bone cell function, despite normal or increasing bone mineral density (BMD). The purpose of this study was to see the relation between duration of diabetes mellitus and BMD in postmenopausal female diabetic patient with diabetic retinopathy

Methods: This cross-sectional study was conducted at the Department of Ophthalmology, BIRDEM General Hospital, Dhaka, Bangladesh during June 2019 to March 2021. After completing their entire ophthalmic examination, 68 post-menopausal female patients between the age of 45 and 70 who had type 2 diabetes with or without diabetic retinopathy (34 in each group) were chosen by using a non-probability sampling technique. After receiving informed written consent, they underwent BMD testing (of lumbar spine and femoral neck) at the Institute of Nuclear Medicine and Allied Science (INMAS) by using dual energy x-ray absorptiometry.

Results: The mean BMD of lumbar spine was found -2.25 ± 0.91 in diabetic retinopathy group and -1.69 ± 0.99 in without diabetic retinopathy group. The difference was statistically significant ($p < 0.05$). The mean BMD of femoral neck was found -2.4 ± 0.9 in diabetic retinopathy group and -1.9 ± 1.1 in without diabetic retinopathy group. The difference was statistically significant ($p < 0.05$). There was a negative correlation between the duration of diabetes mellitus and the BMD of the lumbar spine ($r = -0.699$; $p = 0.001$) and the femoral neck ($r = -0.695$; $p = 0.001$) in diabetic retinopathy patients. There was a negative correlation between the duration of menopause and the BMD of the lumbar spine ($r = -0.405$, $p = 0.018$) and the femoral neck ($r = -0.395$, $p = 0.021$) in diabetic retinopathy patients. There was also a negative correlation between the duration of diabetes mellitus and the BMD of the lumbar spine ($r = -0.418$; $p = 0.014$) and the femoral neck ($r = -0.384$; $p = 0.025$) in without diabetic retinopathy patients. Negative correlation was also found between the duration of menopause and the BMD of the lumbar spine ($r = -0.785$; $p = 0.001$) and the femoral neck ($r = -0.802$; $p = 0.001$) in without diabetic retinopathy patients. But in case of diabetic retinopathy patient there was more statistically significant reduction of BMD with increasing duration of DM.

Conclusion: Patients with diabetes mellitus for a longer period of time with diabetic retinopathy have considerably lower lumbar spine and femoral neck BMD than patients without diabetic retinopathy.

Key word: bone mineral density, diabetic retinopathy, duration.

BIRDEM Med J 2024; 14(1): 16-22

DOI: <https://doi.org/10.3329/birdem.v14i171013>

Author information

- Maria Siddika Mira, Registrar, Department of Ophthalmology, BIRDEM General Hospital & IMC, Dhaka, Bangladesh
- Zinat Jahan Ruma, Consultant, Dristi Eye Hospital, Fellow, Glaucoma, Vision Eye Hospital, Dhaka, Bangladesh
- Purabi Rani Debnath, Professor and Head, Department of Ophthalmology, BIRDEM General Hospital & IMC, Dhaka, Bangladesh

Address of correspondence: Maria Siddika Mira, Registrar, Department of Ophthalmology, BIRDEM General Hospital & IMC; Dhaka, Bangladesh. Email: mirahasan28@gmail.com

Received: July 21, 2023

Revision received: December 21, 2023

Accepted: December 26, 2023

INTRODUCTION

Diabetes mellitus (DM) is a metabolic disease characterized by chronic hyperglycemia, which causes a variety of pathologies such as nephropathy, retinal disease, neuropathy and bone disease.¹ Diabetic retinopathy is a complication of diabetes, caused by high blood sugar levels damaging the eye. Globally, diabetic retinopathy affects more than 103.12 million people. Diabetic retinopathy is among the leading causes of vision loss at the global level.²

Duration of DM seems to be an important risk factor for fractures.³ It is well known that chronic hyperglycemia affects bone health causing fragility, mechanical strength reduction and increased propensity of fracture, because of impaired bone matrix microstructure and aberrant bone cell function although normal or increased bone mineral density (BMD).⁴ Hyperglycemia can directly affect bone health in many different ways including the induction of chronic inflammatory state. High blood glucose levels can increase urinary calcium excretion and can interfere with parathyroid hormone and vitamin D axis leading to hypocalcaemia, suppression of parathyroid hormone (PTH) secretion and impaired vitamin D status.⁵ Several diabetic complications including nephropathy, retinopathy and peripheral neuropathy are associated with a higher fracture risk in diabetic patients.⁶ The prevalence of osteoporosis or osteopenia in the diabetic men with retinopathy do not differ from those without retinopathy.⁶ Another study shows that microangiopathy is independently and negatively correlated with BMD in female.⁷ This study was designed to evaluate the correlation between BMD and diabetic retinopathy in post-menopausal female diabetic patients.

METHODS

This cross-sectional study was conducted in the Department of Ophthalmology, BIRDEM General Hospital, Dhaka, Bangladesh during June 2019 to March 2021. Total 68 female patients with or without diabetic retinopathy, admitted or attending OPD at department of ophthalmology of BIRDEM General Hospital, Dhaka were included in this study. Postmenopausal female patients with type 2 DM (with or without retinopathy), duration of DM >10 years and normal body mass index (BMI) (18.5-22.9 Kg/m²) were included in this study. Those who had other co-morbidity like heart disease, kidney disease or malignancy, alcoholic and/or smoker,

patients who refused to participate, abnormal lipid profile or abnormal serum creatinine, taking bisphosphonate therapy, taking calcium or vitamin D for consecutive months or years were excluded in this study. Sample was selected through non-probability sampling method. Sample were selected after having complete ophthalmic examination consisting of best corrected visual acuity by using Snellen chart, slit lamp biomicroscopy, fundoscopic examination. BMI was calculated by dividing body weight by height squared (kg/m²). Colour fundus photography, Fundus Fluorescein Angiography (FFA), was done as per need after doing fundoscopic examination. Laboratory data like blood glucose, HbA1c, serum creatinine, serum lipid profile was taken from hospital record (diabetic book). BMD was tested by dual energy x-ray absorptiometry of the patient (lumber spine and femoral neck). A questionnaire was filled up for every patient. Chi-square test with Yates correction was used to analyze the categorical variables shown with cross tabulation. Student t-test was used for continuous variables. Pearson's correlation coefficient was used to test the relationship between the groups. P values <0.05 was considered as statistically significant.

RESULTS

Total patients were 64, 34 in each group (with and without diabetic retinopathy). Mean age was 56.6±6.2 years in diabetic retinopathy group and 56.0±6.5 years in without diabetic retinopathy group. The mean duration of diabetes mellitus was 14.3±2.1 years in diabetic retinopathy group and 13.4±1.4 years in without diabetic retinopathy group. Duration of diabetes mellitus was statistically significant (p<0.05) between two groups (Table I). Table II shows that more than half (52.9%) patients had osteopenia and 13 (38.2%) had osteoporosis of lumber spine in diabetic retinopathy group; whereas 14 (41.2%) and 9 (26.5%) respectively in without diabetic retinopathy group. The mean BMD of lumbar spine was found -2.25±0.91 in diabetic retinopathy group and -1.69±0.99 in without diabetic retinopathy group. The difference was statistically significant (p<0.05). More than half (52.9%) patients had osteopenia and 13 (38.2%) have osteoporosis of femoral neck in diabetic retinopathy group; whereas 14 (41.2%) and 9 (26.5%) respectively in without diabetic retinopathy group. The mean BMD of femoral neck was found -2.4±0.9 in diabetic retinopathy group and -1.9±1.1

in without diabetic retinopathy group. The difference was statistically significant ($p < 0.05$). There was a negative correlation ($r = -0.699$; $p = 0.001$) between duration of diabetes mellitus and BMD of lumbar spine of patients with diabetic retinopathy (Figure 1). There was a negative correlation ($r = -0.405$; $p = 0.018$) between duration of menopause and BMD of lumbar spine of patients with diabetic retinopathy (Figure 2). There was a negative correlation ($r = -0.695$; $p = 0.001$) between duration of diabetes mellitus and BMD of femoral neck of patients with diabetic retinopathy (Figure 3) and a negative correlation ($r = -0.395$; $p = 0.021$) between duration of menopause and BMD of femoral neck of

patients with diabetic retinopathy (Figure 4). There was a negative correlation ($r = -0.418$; $p = 0.014$) between duration of diabetes mellitus and BMD of lumbar spine of patients without diabetic retinopathy (Figure 5). There was a negative correlation ($r = -0.785$; $p = 0.001$) between duration of menopause and BMD of lumbar spine of patients without diabetic retinopathy (Figure 6). There was a negative correlation ($r = -0.384$; $p = 0.025$) between duration of diabetes mellitus and BMD of femoral neck of patients without diabetic retinopathy (Figure 7) and a negative correlation ($r = -0.802$; $p = 0.001$) between duration of menopause and BMD of femoral neck of patients with diabetic retinopathy (Figure 8).

Table I. Baseline characteristics of the study patients (N=68)

	Diabetic retinopathy (n=34)		Without diabetic retinopathy (n=34)		P value
	n	%	n	%	
	Age (years)				
	45-50	3	8.8	6	17.6
	51-55	13	38.2	10	29.4
	56-60	10	29.4	10	29.4
	61-65	4	11.8	5	14.7
	>65	4	11.8	3	8.8
Mean \pm SD	56.6	± 6.2	56.0	± 6.5	0.718 ^{ns}
Duration of diabetes mellitus (years)					
	<15	26	76.5	33	97.1
	≥ 15	8	23.5	1	2.9
Mean \pm SD	14.3	± 2.1	13.4	± 1.4	0.041 ^s

s= significant; ns= not significant

P value reached from unpaired t-test

Table II. Lumbar spine of the study patients (N=68)

Lumbar spine	Diabetic retinopathy (n=34)		Without diabetic retinopathy (n=34)		P value
	n	%	n	%	
	Normal	3	8.8	11	
Osteopenia	18	52.9	14	41.2	
Osteoporosis	13	38.2	9	26.5	
Mean \pm SD	-2.25	± 0.91	-1.69	± 0.99	0.018 ^s
Range (min-max)	-3.5	-(-0.1)	-3.1	-(-0.1)	

s= significant

P value reached from unpaired t-test

Table III. BMD of femoral neck of the study patients (N=68)

BMD of femoral neck	Diabetic retinopathy (n=34)		Without diabetic retinopathy (n=34)		P value
	n	%	n	%	
Normal	3	8.8	11	32.4	0.024 ^s
Osteopenia	18	52.9	14	41.2	
Osteoporosis	13	38.2	9	26.5	
Mean ±SD	-2.4	±0.9	-1.9	±1.1	
Range (min-max)	-3.6	-(-0.3)	-3.5	-(-0.1)	

s= significant

P value reached from unpaired t-test

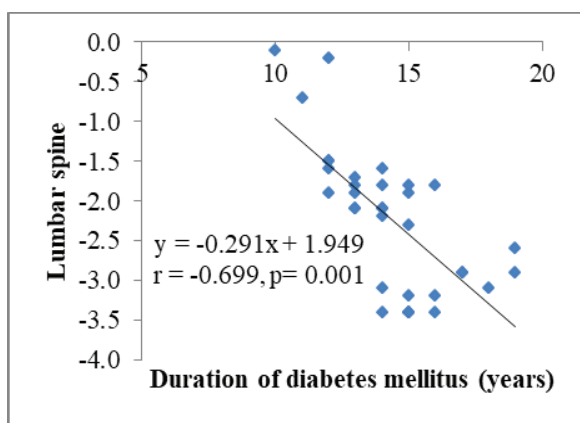


Figure 1. Scatter diagram showing negative correlation ($r = -0.699$; $p = 0.001$) between duration of diabetes mellitus and BMD of lumbar spine of patients with diabetic retinopathy

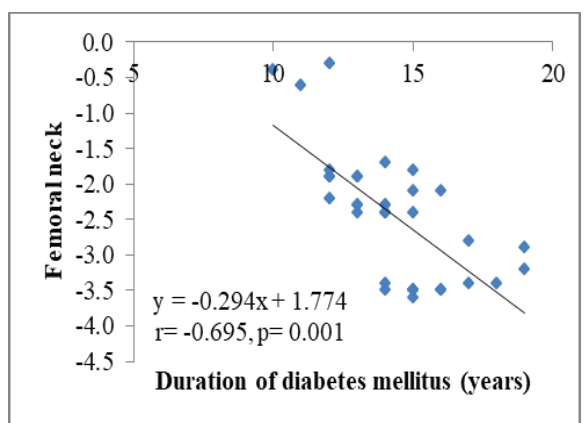


Figure 3. Scatter diagram showing negative correlation ($r = -0.695$; $p = 0.001$) between duration of diabetes mellitus and BMD of femoral neck of patients with diabetic retinopathy

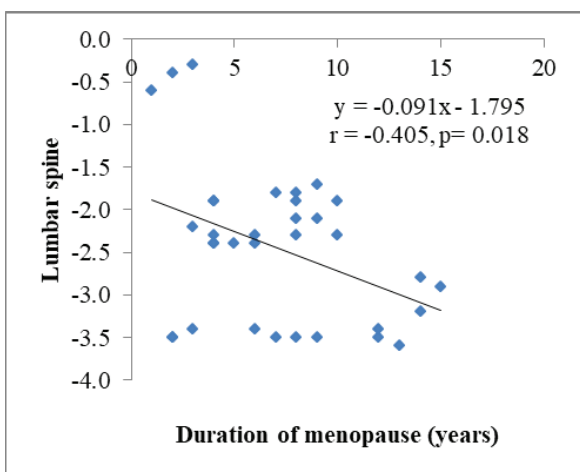


Figure 2. Scatter diagram showing negative correlation ($r = -0.405$; $p = 0.018$) between duration of menopause and BMD of lumbar spine of patients with diabetic retinopathy

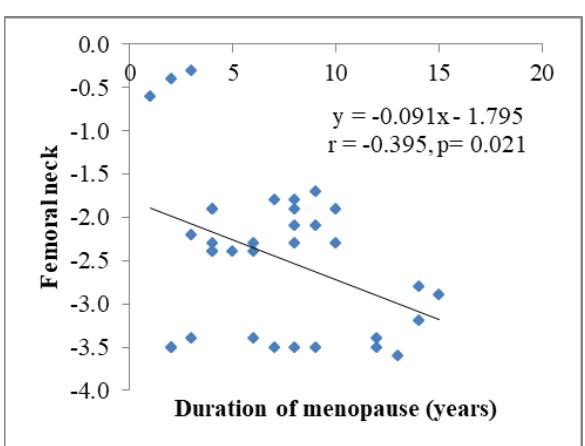


Figure 4. Scatter diagram showing negative correlation ($r = -0.395$; $p = 0.021$) between duration of menopause and BMD of femoral neck of patients with diabetic retinopathy.

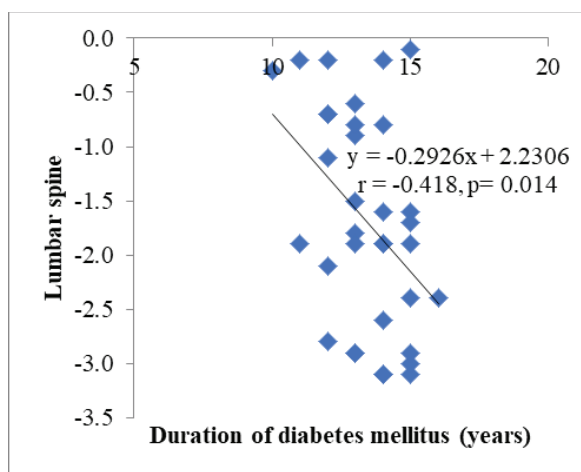


Figure 5. Scatter diagram showing negative correlation ($r = -0.418$; $p = 0.014$) between duration of diabetes mellitus and BMD of lumbar spine of patients without diabetic retinopathy

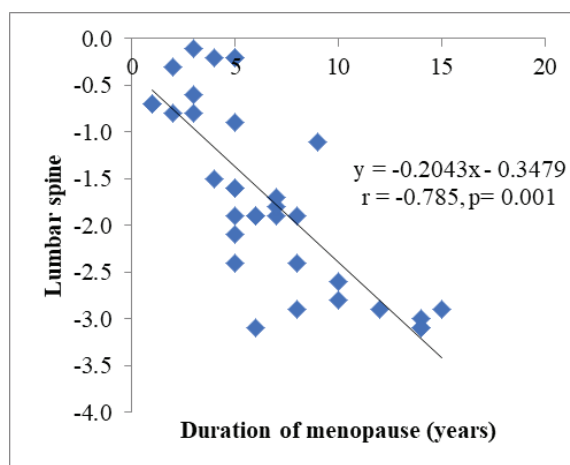


Figure 6. Scatter diagram showing negative correlation ($r = -0.785$; $p = 0.001$) between duration of menopause and BMD of lumbar spine of patients without diabetic retinopathy

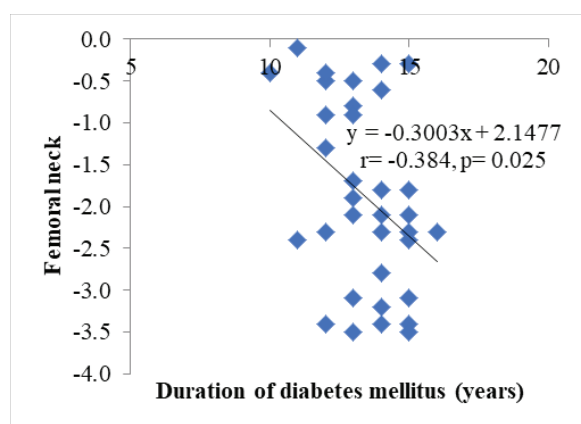


Figure 7. Scatter diagram showing negative correlation ($r = -0.384$; $p = 0.025$) between duration of diabetes mellitus and BMD of femoral neck of patients without diabetic retinopathy

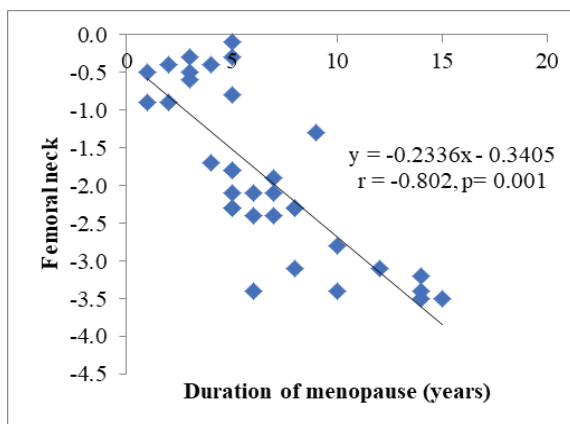


Figure 8. Scatter diagram showing negative correlation ($r = -0.802$; $p = 0.001$) between duration of menopause and BMD of femoral neck of patients without diabetic retinopathy.

DISCUSSION

In present study we found that mean age was over 56 years in both the groups. Lim et al.⁶ reported the mean age was found 66.25±1.40 years in diabetic retinopathy group and 66.36±0.48 years in without diabetic retinopathy group. Siddapur et al.⁸ study also found that no significant difference was the mean age in diabetic retinopathy and without diabetic retinopathy groups.

In this study, mean duration of diabetes mellitus was over 14 years in diabetic retinopathy group and over 13 years in without diabetic retinopathy group. Lim et al.⁶

reported the mean duration of diabetes mellitus was found 10.80±1.13 years in diabetic retinopathy group and 7.22±0.44 years in without diabetic retinopathy group.

We found that more than half of our patients had osteopenia and nearly 40% had osteoporosis of lumbar spine in diabetic retinopathy group whereas over 40% and more than one-fourth respectively in without diabetic retinopathy group. The mean BMD of lumbar spine was found -2.25±0.91 in diabetic retinopathy group and -1.69±0.99 in without diabetic retinopathy group.

Siddapur et al.⁸ reported T-score was significantly higher in diabetics compared with non-diabetics (“2.84±0.42 vs. “3.22±0.74, $P < 0.05$). Raj et al.⁹ observed that the mean spine BMD was found 0.90±0.16 score in diabetic group and 0.87±0.15 score in without diabetic group. The difference was not statistically significant ($p > 0.05$) between two group.

In this study we observed that more than half of the patients have osteopenia and nearly 40% had osteoporosis of femoral neck in diabetic retinopathy group whereas over 40% and one-fourth respectively in without diabetic retinopathy group. The mean BMD of femoral neck was found -2.4±0.9 in diabetic retinopathy group and -1.9±1.1 in without diabetic retinopathy group. Lim et al.⁶ reported the diabetic women with retinopathy were more likely to have osteopenia (56.9 vs 43.3%) or osteoporosis (41.9 vs 30.5%) compared to those without retinopathy.

Axial BMD is typically normal or higher in patients with type 2 diabetes because BMI is a major determinant of BMD and type 2 DM is typically associated with obesity.¹⁰ Therefore, the association between BMD and diabetic retinopathy might be related to the activity of a sex steroid. Estrogen has vasoactive effects and reduces resistance in ocular vascular beds and protective effects against some ocular diseases.¹¹ Asokan et al.¹² interestingly, and some other studies had shown diabetes as a promoter for bone health.

In current study we observed the negative correlation between duration of diabetes mellitus and BMD of lumbar spine of patients with diabetic retinopathy. Negative association was observed between the duration of diabetes and BMD of femoral neck also. These results were consistent with findings of Wakasugi et al.¹³ and Kao et al.¹⁴ They demonstrated duration of diabetes as a risk factor for decreased BMD in type 2 diabetic subjects.

In present study, there is negative correlation between duration of diabetes mellitus and BMD of femoral neck of patients with and without diabetic retinopathy. There is a negative correlation between duration of menopause and BMD of femoral neck of patients with and without diabetic retinopathy. De Waard et al.¹⁵ observed no association between BMD and the presence of prevalent vertebral fractures in type 2 diabetic patients,^{16,17} but a large trial that used the prospective

data from three observational studies found a negative association between femoral neck T-score and hip and non-spine fracture risk.¹⁸

In conclusion, diabetes duration was found to have a significant relation with diabetic retinopathy. In diabetic retinopathy patients, there was a negative relationship between the long duration of diabetes, the duration of menopause and the BMD of both the lumbar spine and the femoral neck. More negative correlations were discovered between the duration of diabetes mellitus and the BMD of the lumbar spine and femoral neck in individuals with diabetic retinopathy compared to those without diabetic retinopathy.

Authors' contribution: MSM planned the study, collected and analyzed data. ZJR, PRD authors contributed to collect and drafting the manuscript. All authors read and approved the final manuscript for publication.

Funding: The research was partially funded by Bangladesh Medical Research Council (BMRC).

Conflicts of interest: Nothing to declare.

REFERENCES

1. Carnovali M, Luzi L, Banfi G, Mariotti M. Chronic hyperglycemia affects bone metabolism in adult zebrafish scale model. *Endocrine* 2016;54:808-17.
2. Gelcho GN, Gari FS. Time to Diabetic Retinopathy and Its Risk Factors among Diabetes Mellitus Patients in Jimma University Medical Center, Jimma, Southwest Ethiopia. *Ethiop J Health Sci* 2022;32(5):937.
3. Dede AD, Tournis S, Dostas I, Trovas G. Type 2 diabetes mellitus and fracture risk. *Metabolism* 2014;63(12):1480-90.
4. Wongdee K, Charoenphandhu N. Update on type 2 diabetes-related osteoporosis. *World Journal of Diabetes* 2015;6(5):673.
5. Napoli N, Strollo R, Paladini A, Briganti SI, Pozzilli P, Epstein S. The alliance of mesenchymal stem cells, bone, and diabetes. *International Journal of Endocrinology* 2014;2014:1-26.
6. Lim Y, Chun S, Lee JH, Baek KH, Lee WK, Yim HW, et al. Association of bone mineral density and diabetic retinopathy in diabetic subjects: the 2008–2011 Korea National Health and Nutrition Examination Survey. *Osteoporosis International* 2016;27:2249-57.
7. Zhong N, Zhang Y, Pu X, Xu B, Xu M, Cai H, et al. Microangiopathy is associated with bone loss in female type 2 diabetes mellitus patients. *Diabetes and Vascular Disease Research* 2018;15(5):433-41.

8. Siddapur PR, Patil AB, Borde VS. Comparison of bone mineral density, T-scores and serum zinc between diabetic and non diabetic postmenopausal women with osteoporosis. *Journal of Laboratory Physicians* 2015;7(01):43-8.
9. Raj S, Baiju SJ, Vijayan R, Rajan GV. Association between Bone Mineral Density and Type 2 Diabetes Mellitus-An Original. *British Journal of Research* 2014;1-2:63-7.
10. Gilbert MP, Pratley RE. The impact of diabetes and diabetes medications on bone health. *Endocrine Reviews* 2015;36(2):194-213.
11. Faria AF, de Souza MA, Geber S. Vascular resistance of central retinal artery is reduced in postmenopausal women after use of estrogen. *Menopause* 2011;18(8):869-72.
12. Asokan AG, Jaganathan J, Philip R, Soman RR, Sebastian ST, Pullishery F. Evaluation of bone mineral density among type 2 diabetes mellitus patients in South Karnataka. *Journal of Natural Science, Biology, and Medicine* 2017;8(1):94-8.
13. Wakasugi M, Wakao R, Tawata M, Gan N, Koizumi K, Onaya T. Bone mineral density measured by dual energy x-ray absorptiometry in patients with non-insulin-dependent diabetes mellitus. *Bone* 1993;14(1):29-33.
14. Kao WL, Kammerer CM, Schneider JL, Bauer RL, Mitchell BD. Type 2 diabetes is associated with increased bone mineral density in Mexican-American women. *Archives of Medical Research* 2003;34(5):399-406.
15. De Waard EA, van Geel TA, Savelberg HH, Koster A, Geusens PP, Van Den Bergh JP. Increased fracture risk in patients with type 2 diabetes mellitus: an overview of the underlying mechanisms and the usefulness of imaging modalities and fracture risk assessment tools. *Maturitas* 2014;79(3):265-74.
16. Yamamoto M, Yamaguchi T, Yamauchi M, Kaji H, Sugimoto T. Bone mineral density is not sensitive enough to assess the risk of vertebral fractures in type 2 diabetic women. *Calcified Tissue International* 2007;80:353-8.
17. Yamaguchi T, Yamamoto M, Kanazawa I, Yamauchi M, Yano S, Tanaka N, et al. Quantitative ultrasound and vertebral fractures in patients with type 2 diabetes. *Journal of Bone and Mineral Metabolism* 2011;29:626-32.
18. Schwartz AV, Vittinghoff E, Bauer DC, Hillier TA, Strotmeyer ES, Ensrud KE, et al. Association of BMD and FRAX score with risk of fracture in older adults with type 2 diabetes. *JAMA* 2011;305(21):2184-92.