

Scattered finding of Acute Severe Aortic Regurgitation in a Child with Ventricular Septal Defect: Floating Non Coronary Cusp Due to Rupture Fibrous Strands

Mohammad Eliyas Patwary

(Bangladesh Heart Journal 2024; 39(2): 177-178)

Introduction:

Acute severe aortic regurgitation (AR) by rupture of a fibrous strands of aortic valve is a rare condition specially in child. Here we discuss a male kid of 14 months diagnosed case of ventricular septal defect (VSD) mild AR with moderate mitral regurgitation (MR), with severe pulmonary arterial hypertension (PAH) was admitted into hospital for elective surgery. Day before surgery we found severe acute AR with floating Non coronary cusp (NCC) into aorta. Peroperative findings suggested that due to

rupture of the fibrous strands from aortic wall along with endothelial flap suspending NCC onto aorta.

Case presentation:

A 1 year 2 months boy presented with recurrent respiratory tract infection with 7 kilogram body weight, diagnosed large perimembranus VSD, mild AR, moderate MR with Severe PAH. Planned for elective open heart surgery. After admission patient diagnosis was changed with severe aortic regurgitation with suspending non coronary cusp (NCC) into aorta.

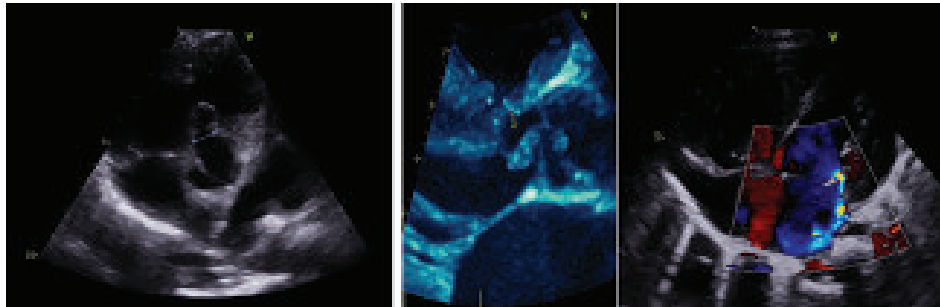


Figure 1: Preoperative Echocardiogram

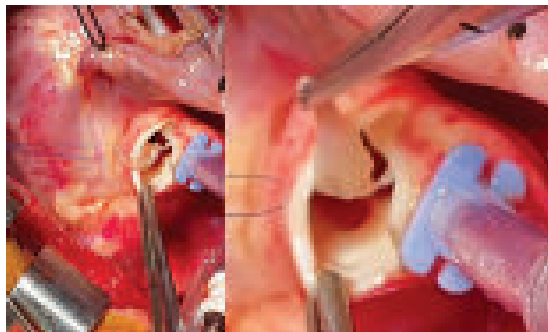


Figure 2: Operative view of ruptured fibrous strands with floating NCC.

Address of Correspondence: Dr Md Eliyas Patwary, Associate Prof. of Pediatric Cardiac Surgery, National heart foundation hospital. Dhaka. Mobile: 01739120984, E-mail: patwarye@yahoo.com

DOI: <https://doi.org/10.3329/bhj.v39i2.75809>

Copyright © 2017 Bangladesh Cardiac Society. Published by Bangladesh Cardiac Society. This is an Open Access articles published under the Creative Commons Attribution-NonCommercial 4.0 International License (CC BY-NC). This license permits use, distribution and reproduction in any medium, provided the original work is properly cited and is not used for commercial purposes.

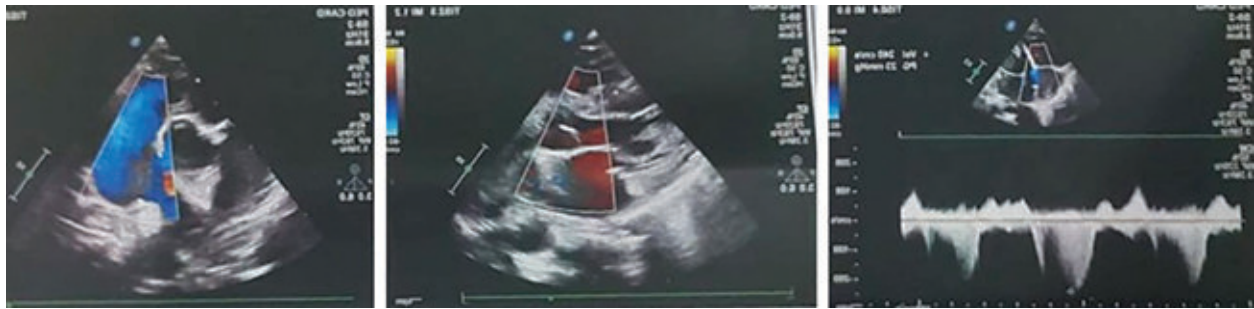

Figure 3: Postoperative Echo after 6 month follow up.

Discussion:

Acute severe aortic regurgitation in very early age is rare, no case yet recorded. In my case I assumed that the congenital fibrous strands arising from the aortic wall and suspending aortic valvular apparatus, suddenly ruptured by the jet of pulmonary hypertensive flow causing acute loss of leaflet support and subsequent torrential aortic regurgitation. Only one clue was the kid had history of sneeze last night, that may rise mechanical pressure on it. Echocardiography, blood parameters, clinical parameters ruled out infective endocarditis as the provoking factor.

However this type of aortic regurgitation may be found embryonic remnants supporting aortic valve leaflets and associated with such pathology¹. In publications, some adult cases of acute AR is caused by either infective endocarditis of the aortic valve itself or an aortic dissection, bicuspid aortic valve or in rare cases by traumatic rupture of aortic valve²⁻⁴. But this issue never reported into child at this age group with normal tricuspid aortic valve.

This patient was stable hemodynamically due to large VSD with moderate MR and operated with antegrade coronary cardioplegia. During repair we got small remnant attached to aortic wall that helped us accommodate the torn NCC on its native place directly

with 8/0 prolene continuous suture good coaptation. The fibrous strands fixed at supra commissural area with multiple pledgeted 6/0 prolene suture from outside of the aortic wall.

Finally, the existing fibrous strands involving suspension of coronary cusp is suitable for repair of aortic valve incompetence in children because this young patient having normal all cusp. Our patient had very good postoperative outcome at 6 month follow up.

References:

1. Abdelaziz MM, Martinelli G, Luckraz H. Chordae tendineae of the aortic valve. J Card Surg. 2016;31(5):328-329.
2. Yuan S, Mou R, Sun X, Mou Y. Aortic chordae tendineae strands with significant aortic regurgitation. Int Heart J. 2021;62(5):1160-1163.
3. Bouchachi AA, Folliguet T, Hébert JL, et al. A severe restrictive aortic regurgitation resulting from valve tenting by unusual aortic chordae tendineae strands. Circulation. 2012;126:e139-e141.
4. Esteve Ruiz I, López Pardo F, Lagos Degrande Ó, López Haldón JE, Urbano Moral JA. Severe restrictive aortic regurgitation due to aortic fibrous strand. Eur Heart J Cardiovasc Imaging. 2015;16:465.