

## Clinical Image

# A case of Iatrogenic Pseudo Aneurysm of Femoral Artery

Mir Atiqur Rahman<sup>1</sup>, Umme Kulsum Chy<sup>2</sup>, Amina Sultana<sup>3</sup>, Mohammad Omar Faruq<sup>4</sup>

DOI: <https://doi.org/10.3329/bccj.v12i2.76366>

### Case:

A 55-year-old woman was admitted to hospital in-patient unit with fever and breathlessness for 5 days. Pertinent medical history included chronic kidney disease (CKD), poorly controlled Diabetes with retinopathy, Hypertension and Bronchial asthma. After admission patient was found to be severely anaemic and her stool was black and tarry. Blood transfusion was required for correction of anaemia. Endoscopy of upper GIT was planned after stabilization. RT PCR for COVID-19 was positive. After couple of days she became desaturated in spite of high level of oxygen delivery and was shifted to ICU.

Few days after admission into ICU she developed AKI which needed urgent haemodialysis. Initially a dialysis catheter was attempted in to right femoral vein. But accidentally artery was punctured. Heamostasis was done by pressure bandage applied on site of puncture. Later HD catheter was inserted through left femoral route and dialysis was completed uneventfully.

Three days later she developed swelling of right thigh and Doppler USG study showed pseudoaneurysm of right femoral artery with diffuse haematoma. Gradually right leg became hugely swollen, tender and patient became haemodynamically unstable. Patient was found to have increased bleeding tendency and altered coagulation profile. Several units of FFP, PRBC and platelets from Platelet Apheresis were transfused.

After stabilization Doppler ultra-sonogram showed pseudoaneurysm of right femoral vessel (blue arrow Fig 1-A). CT angiogram of right lower limb was done and it showed pseudoaneurysm in right groin arising from the anterior wall of right superficial femoral artery (blue arrow Fig 1-B).

Pseudoaneurysm excision and repair of right superficial femoral artery with evacuation of haematoma were done. After surgery, right leg swelling gradually decreased and patient clinically improved.

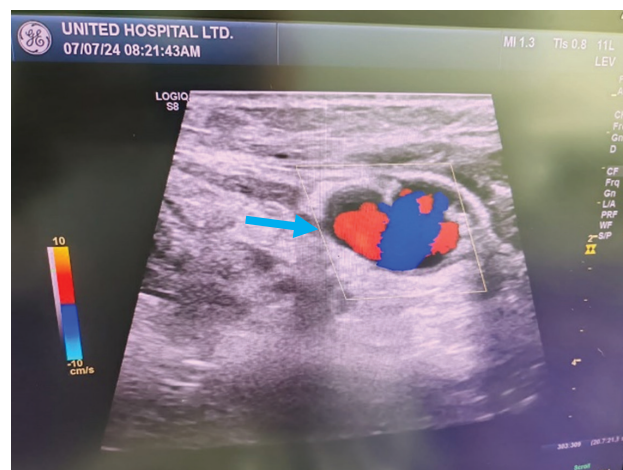


Fig 1-A

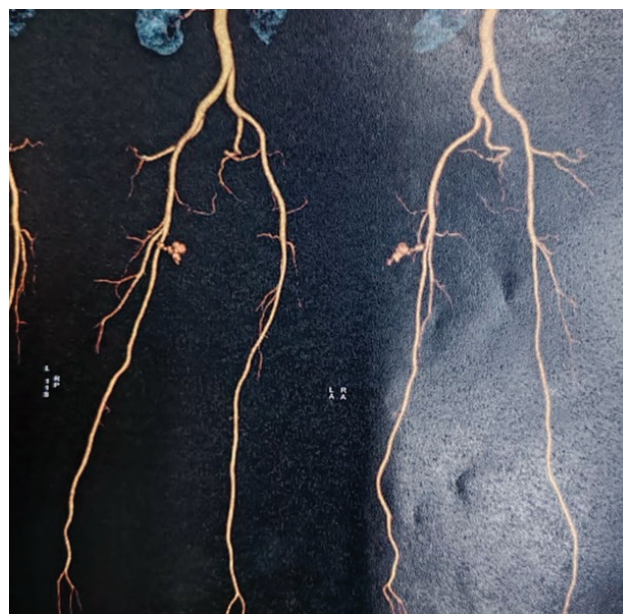

Fig 1-B

1. Specialist, Critical Care Medicine (CCM), United hospital Ltd, Dhaka 1212. Bangladesh.
2. Associate Consultant, CCM, United hospital Ltd, Dhaka 1212. Bangladesh.
3. Consultant, CCM & Emergency Medicine (EM). United hospital Ltd, Dhaka 1212. Bangladesh.
4. Chief Consultant, CCM & EM, United hospital Ltd, Dhaka 1212. Bangladesh.

### Corresponding Author:

Dr. Mir Atiqur Rahman  
Specialist, Critical Care Medicine  
United hospital Ltd, Dhaka 1212. Bangladesh.  
E mail: mars\_0105@yahoo.com

### Discussion:

The femoral artery pseudoaneurysm (FAP) is a troublesome groin complication related to the femoral arterial access site used for invasive vascular procedures<sup>1</sup>. FAP occur in 0.8% to 2.2% following interventional procedures<sup>2</sup>.

Iatrogenic pseudoaneurysms (IPA) form when an arterial puncture site fails to seal, allowing arterial blood to jet into the surrounding tissues and form a pulsatile hematoma. These lesions lack a fibrous wall and are contained by a surrounding shell of hematoma and the overlying soft tissues. It can present as a new thrill or bruit, pulsatile hematoma, or marked pain or tenderness. Subcutaneous groin hematoma, which is common in these patients, often masks the pseudoaneurysms. Complications of IPA include rupture, distal embolization, local pain, neuropathy and local skin ischemia<sup>3</sup>.

Beyond the common femoral artery bifurcation, there is no bony support and no tamponade by the femoral sheath, and thus there is a higher incidence of bleeding and formation of an IPA. Altin et al<sup>4</sup> confirmed this hypothesis and demonstrated a low puncture as the cause of 10 out of 11 iatrogenic femoral pseudoaneurysm.

The diagnosis is confirmed by imaging of the pseudoaneurysm. Duplex study has been the diagnostic imaging modality of choice.

Several therapeutic strategies have been developed to treat this complication. They include ultrasound-guided compression repair (UGCR), surgical repair, and minimally invasive percutaneous treatments (thrombin injection, coil embolization and insertion of covered stents).

UGCR has become the first-line treatment of IPA at many institutions. It has significantly reduced the need for surgical repair of FAP. It has been shown to be a safe and cost-effective method for achieving pseudoaneurysm thrombosis<sup>3</sup>.

However, UGCR has considerable drawbacks including long procedure time, discomfort to patients and a relatively high recurrence rate in patients receiving anticoagulant therapy (as high as 25% to 35%).<sup>3</sup> UGCR has been shown to be less successful in patients with large FAP (i.e., larger than 3 cm to 4 cm in diameter) and those who cannot tolerate the associated discomfort<sup>5</sup>.

Moreover, UGCR requires the availability of an ultrasound device and the presence of skilled personnel during the procedure.

Contraindications to this technique include inaccessible site, limb ischaemia, and infection, large hematomas with overlying skin ischaemia, compartment syndrome and prosthetic grafts.

However, there are situations when surgical treatment may be necessary. These are: rapid expansion of IPA, concomitant distal ischaemia, failure of percutaneous compression, compromised soft tissue viability etc. Surgery is usually effective and definitive.

## References:

1. Hamraoui K, Ernst SM, van Dessel PF, Kelder JC, ten Berg JM, Suttorp MJ, et al. Efficacy and safety of percutaneous treatment of iatrogenic femoral artery pseudoaneurysm by biodegradable collagen injection. *J Am Coll Cardiol.* 2002; 39:1297–1304.
2. Messina LM, Brothers TE, Wakefield TW, Zelenock GB, Lindenauer SM, Greenfield LJ, et al. Clinical characteristics and surgical management of vascular complications in patients undergoing cardiac catheterization: interventional versus diagnostic procedures. *J Vasc Surg.* 1991; 13:593–600
3. Eisenberg L, Paulson EK, Kliewer MA, Hudson MP, DeLong DM, Carroll BA. Sonographically guided compression repair of pseudoaneurysms: further experience from a single institution. *AJR Am J Roentgenol.* 1999; 173:1567–1573.
4. Altin RS, Flicker S, Naidech HJ. Pseudoaneurysm and arteriovenous fistula after femoral artery catheterization: association with low femoral puncture Am J Roentgenol. 1989; 152:629-631.
5. O'Sullivan GJ, Ray SA, Lewis JS, Lopez AJ, Powell BW, Moss AH, et al. A review of alternative approaches in the management of iatrogenic femoral pseudoaneurysms. *Ann R Coll Surg Engl.* 1999; 81:226–234.